

## PICTURES IN CLINICAL MEDICINE

From Dept. of Medicine – Mosul College of Medicine

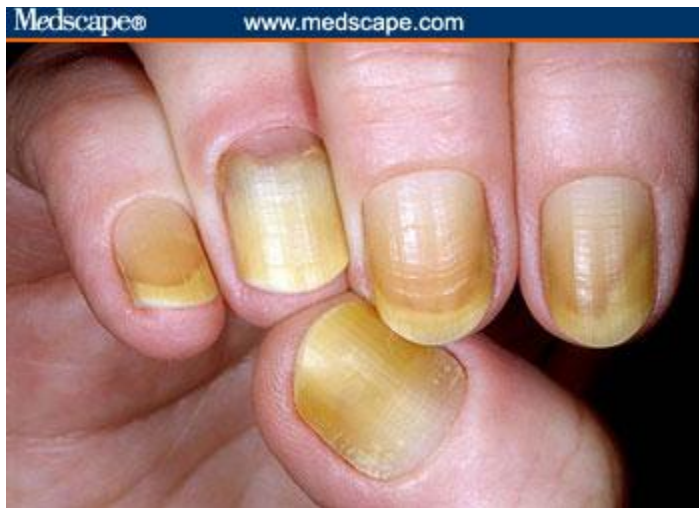for undergraduate students

Every Tuesday we present 5 picture cases. The answers will be available a week later following the presentation.

### New pictures of this week

March 18, 2014. Answers

**This is a patient with bronchiectasis and lymphoema. What is diagnosis?**

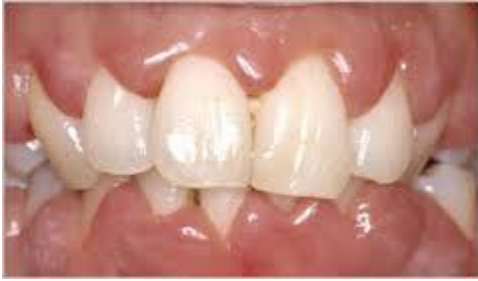

Answer: This a case of yellow-nail syndrome.

**This patient with IHD. What this picture is demonstrating?** Answer: Nicotine staining.

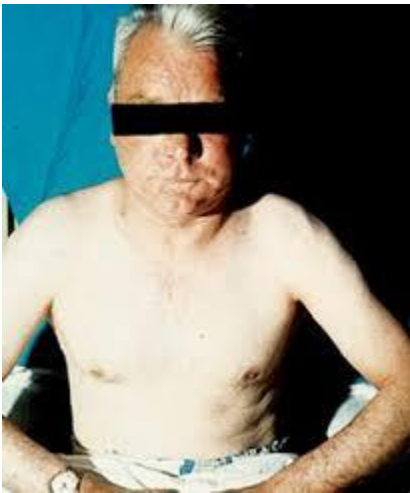


**What are the causes?**

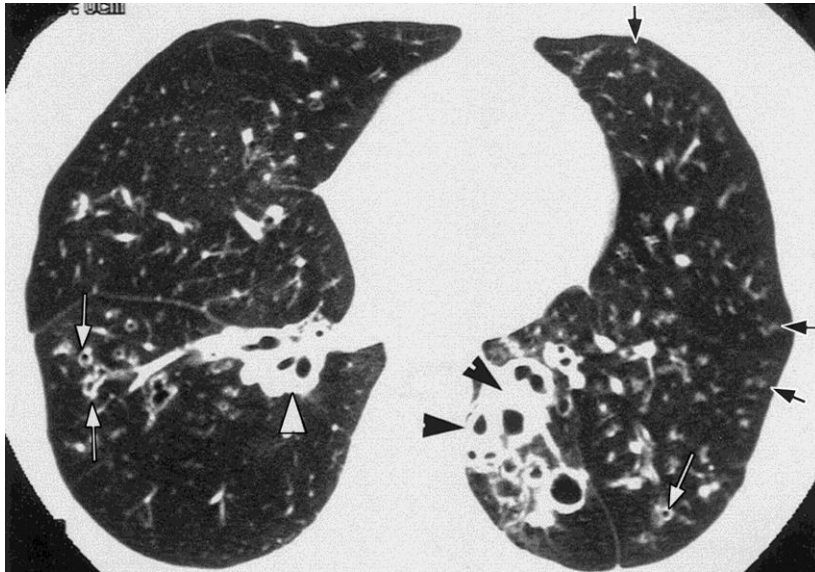


Answer: Gum hyperatropy. In addition to local causes, we have numerous systemic causes like scurvy (also cause bleeding gum), acute myelogenic leukemia, anti-epileptic drug (phenytoin), etc.

**What type of chest deformity is demonstrated in this picture? Mention the expected finding on 4 steps of chest examination?** Answer barrel chest. Increase antero-posterior diameter, short trachea, tracheal tag, accessory muscles over action, hyperresonance chest with impaired cardiac and hepatic dullness, diminished breath sound, prolonged expiratory phase, rhonchi and/or crepitations.



**This is a CT scan of 30-year-old male patient. What are the symptoms and signs that are expected to occur in this patient?**



Answer: Bronchiectasis. Cough productive of large amount of purulent sputum especially at morning, hemoptysis may be a feature. Chest pain may be present. Coarse crepitation over the affected area is expected.

**This is CXR of 55-years- old patient presented with wedge fracture of 3<sup>rd</sup> lumbar vertebra. What is the most likely diagnosis? What are other features of this disease?** Bronchogenic carcinoma. Local: e. g. chest pain, hemoptysis, etc. Systemic: anaemia, metastasis to bone, LN, liver, hornar syndrome, non-metastatic features in small cell carcinoma.

