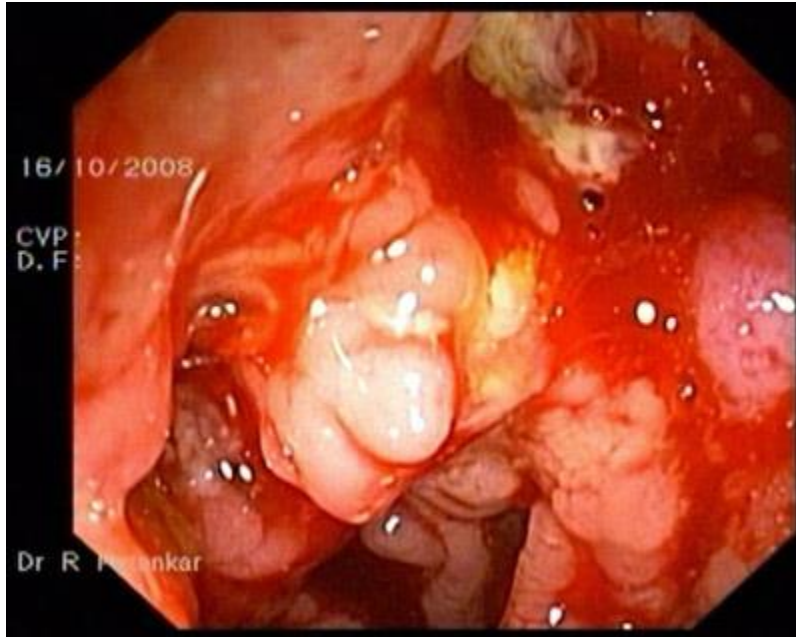
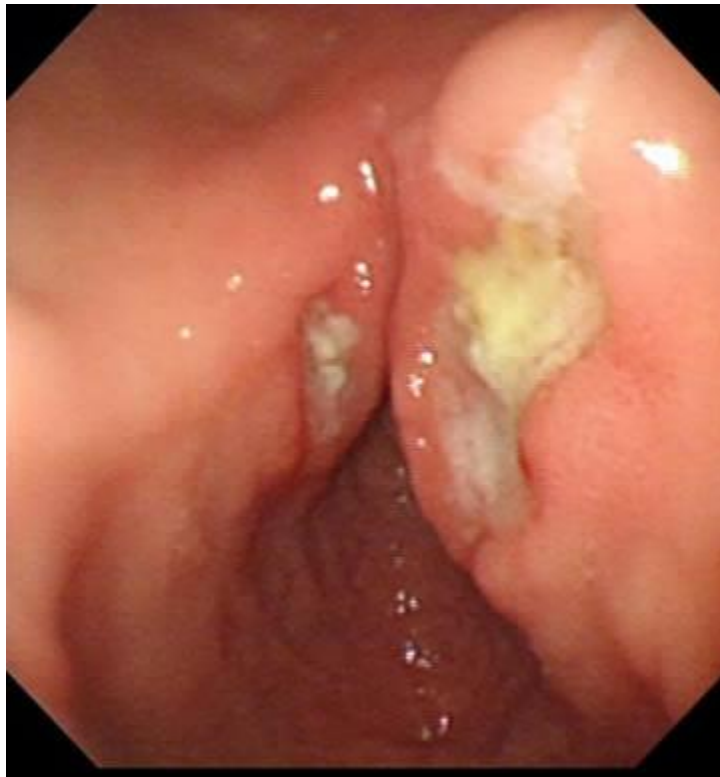

Q1: A 55-year-old male patient presented with bleeding per rectum. Comment on management.

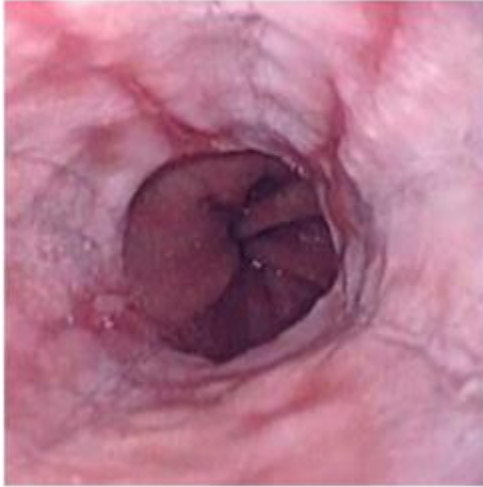


Q2: This is endoscopic finding of a patient with chronic dyspepsis. Give diagnosis. Outline the management.

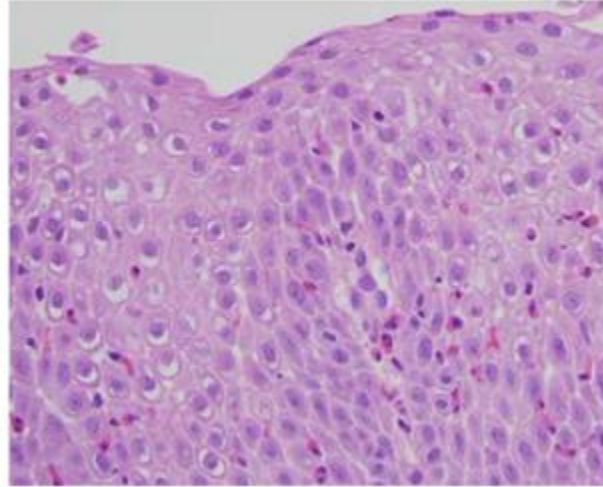


Q3: This patient is presented with hoarseness of voice with cough and wheezy chest. Diagnosis? Treatment.

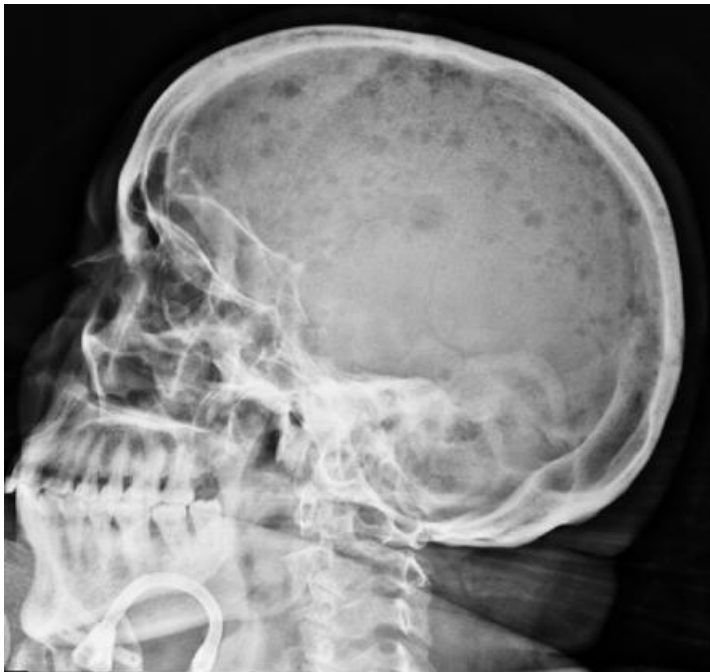a



b



Q4: This is a skull X-ray of 60-year-old man with chronic severe lower back ache and high ESR. What is diagnosis. Comment on prognosis.



Q 5: What are the differential diagnoses?

