

PICTURES IN CLINICAL MEDICINE

From Dept. of Medicine – Mosul College of Medicine

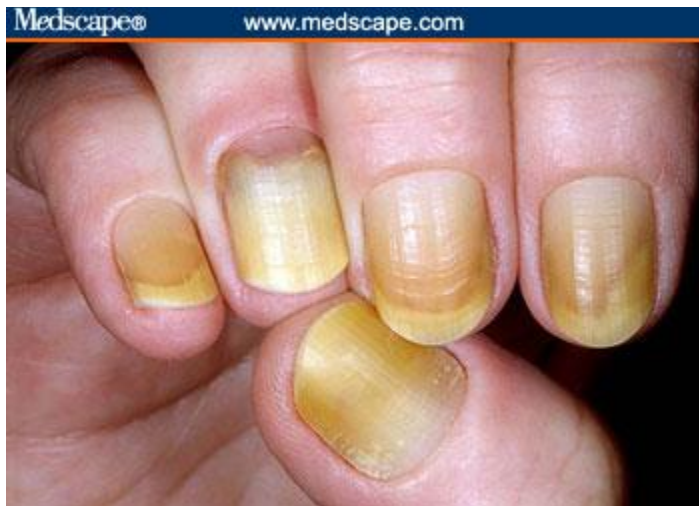for undergraduate students

Every Tuesday we present 5 picture cases. The answers will be available a week later following the presentation.

New pictures of this week

March 18, 2014

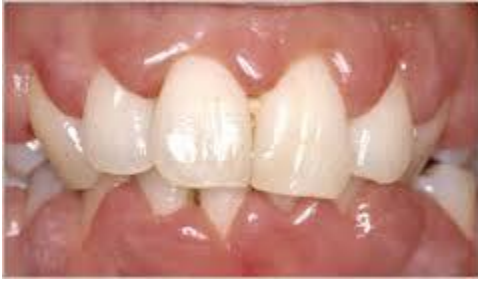This is a patient with bronchiectasis and lymphoema. What is diagnosis?



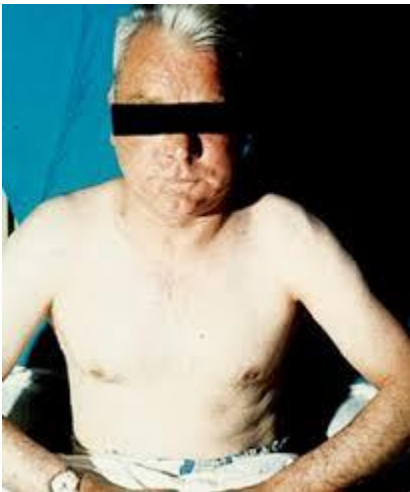
This patient with IHD. What this picture is demonstrating?



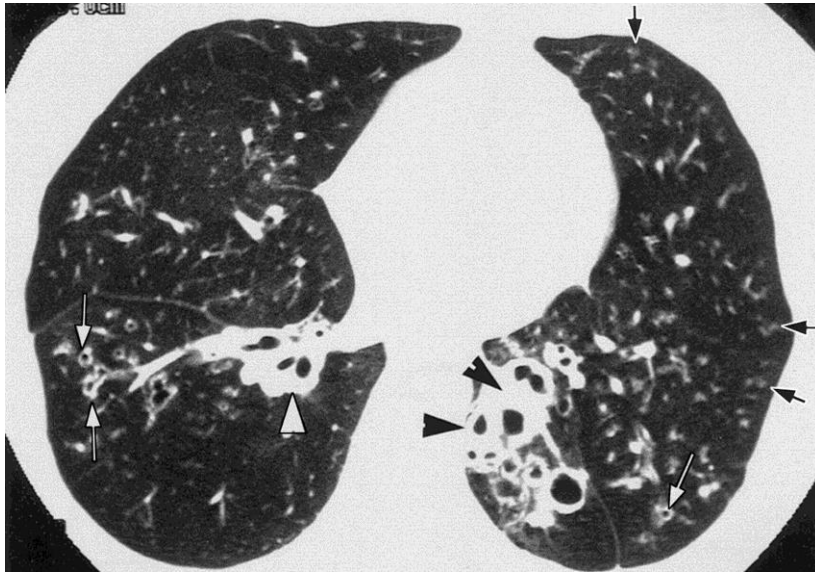
What are the causes?



What type of chest deformity is demonstrated in this picture? Mention the expected finding on 4 steps of chest examination?



This is a CT scan of 30-year-old male patient. What are the symptoms and signs that are expected to occur in this patient?



This is CXR of 55-years- old patient presented with wedge fracture of 3rd lumbar vertebra. What is the most likely diagnosis? What are other features of this disease?

