

PICTURES IN CLINICAL MEDICINE

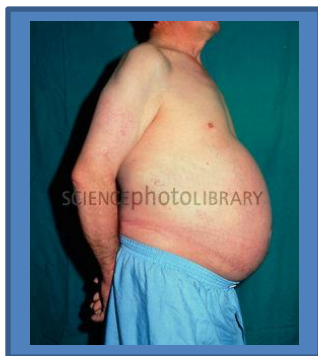From Dept. of Medicine – Mosul College of Medicine

for undergraduate students

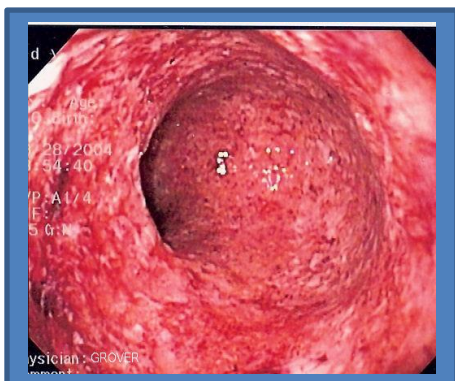
Every Tuesday we present 5 picture cases. The answers will be available a week later following the presentation.

March 25,2014

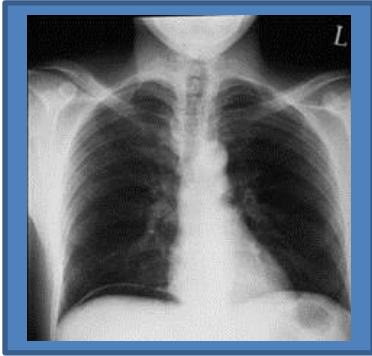
Q1. This man is chronic consumer of alcohol (around 30 units of alcohol/week) for > 20 years, now he presented with history of recent abdominal distention. Mention the possible finding on general and abdominal examination. Comment on prognosis and future planning.



Q2. This is the colonoscopic finding (sigmoid colon) of 30 year old female patient with history of 1 month diarrhea, sometimes containing blood. How you can manage this patient?



Q3. This is chest X-ray of a patient with history of chronic dyspepsia. Mention the finding.



Q4. Enumerate the possible complications of this disease?



Q5. What is the finding? What are the causes?

